

Brain connectivity changes during ictal coughing

Alexandra Roux, Stanislas Lagarde, Aileen Mcgonigal, Fabrice Bartolomei

IN **EPILEPTIC DISORDERS** 2019/4 Vol 21 , PAGES 353 TO 357

PUBLISHER **JLE**

ISSN 1294-9361

DOI 10.1684/epd.2019.1084

Uploaded: 09/16/2024

Article available online at

<https://stm.cairn.info/revue-epileptic-disorders-2019-4-page-353?lang=en>



Discover the contents of this issue, follow the journal by email, subscribe...
Scan this QR code to access the page for this issue on Cairn.info.



Electronic distribution Cairn.info for JLE.

You are authorized to reproduce this article within the limits of the terms of use of Cairn.info or, where applicable, the terms and conditions of the license subscribed to by your institution. Details and conditions can be found at cairn.info/copyright.

Unless otherwise provided by law, the digital use of these resources for educational purposes is subject to authorization by the Publisher or, where applicable, by the collective management organization authorized for this purpose. This is particularly the case in France with the CFC, which is the approved organization in this area.

Brain connectivity changes during ictal coughing

Alexandra Roux¹, Stanislas Lagarde^{2,3}, Aileen McGonigal^{2,3}, Fabrice Bartolomei^{2,3}

¹ Université Clermont-Auvergne, Clermont-Ferrand,

² Aix Marseille Univ, Institut de Neurosciences des Systèmes, Marseille,

³ AP-HM, Hôpital de la Timone, Service d'Epileptologie, Marseille, France

Received January 16, 2019; Accepted June 10, 2019

ABSTRACT – Coughing is a reflex phenomenon that is protective for the upper airways, involving both a reflex arc in the brainstem and cortical control. Ictal coughing has been prominently reported in temporal lobe seizures, but precise anatomo-electrical correlations are lacking. We report a patient who presented with persistent coughing at seizure onset. We studied intracerebrally recorded seizures (using stereo-electroencephalography) in order to describe the anatomo-functional correlations associated with this sign. Coughing followed seizure onset in the medial temporal lobe. A functional connectivity study (h^2 estimation of interdependencies) showed that during coughing, a network of cortical and subcortical regions was involved, particularly the perisylvian cortices and the caudate nucleus.

Key words: SEEG, functional connectivity, cough, focal seizure

Ictal coughing is a rare sign in patients with epilepsy. Prominent and stereotyped ictal coughing has been mainly reported in temporal lobe seizures (Fauser *et al.*, 2004). However, the precise anatomical origin of ictal coughing remains unknown. Coughing is a reflex phenomenon that is protective for the upper airways, occurring when sensitive receptors located in the larynx and upper airways are activated and generate information that reaches the central nervous system (Chang, 2006). The neural organization of the cough reflex is mediated by the Xth and IXth cranial nerve nuclei, the brainstem, and the pons cough centre (Moinard and Manier, 2000). Cortical control may influence this reflex arch. Functional MRI

studies have shown that the cough reflex recruits many cortical areas such as the insular cortex, limbic structures, and sensorimotor cortices (Mazzone *et al.*, 2013). Seizure semiology is not related to the involvement of a unique region but is linked to changes in brain networks involved in seizure propagation (Bartolomei *et al.*, 2013, 2017c). In this context, the study of functional connectivity during seizures has been proposed to quantify the temporo-spatial changes in network properties (Bartolomei *et al.*, 2017c), particularly when focusing on the period during a specific clinical change.

In the present study, we report a case in which, during SEEG-recorded seizures, coughing was the main

Correspondence:

Fabrice Bartolomei
Service d'épileptologie et rythmologie
cérébrale,
CHU Timone,
264 Rue St Pierre 13005,
Marseille, France
<fabrice.bartolomei@ap-hm.fr>

objective sign observed early in the seizure course. We describe both electroclinical SEEG aspects and intracerebral EEG connectivity changes.

Methods

Patient

Among 350 patients explored by SEEG in our centre from 2000, we identified one patient with prominent ictal coughing (0.2%). A 38-year-old female patient underwent presurgical evaluation for her drug-resistant epilepsy in our Epilepsy Unit. She was right-handed and had no particular past medical or family history of note. At the age of 15 years, she had a first secondary generalized seizure with rapid recurrence of seizures. Despite several trials of antiepileptic drugs, she remained pharmacoresistant. Her seizure frequency varied from six to 12 seizures per month. Seizures were stereotyped, with initial subjective signs of rising epigastric sensation and feeling of fear, and simultaneous cough, of which she was conscious. These symptoms were followed by oral automatisms (chewing). A presurgical work-up was conducted at the age of 38 years. Brain magnetic resonance imaging (MRI) (1.5T including Flair sequences) was normal. Four seizures were recorded on video-surface EEG. Semiology began with coughing, change in facial expression (anxiety, fear), then a scream, and finally

chewing automatisms with hypersalivation. There was no impairment of awareness and no aphasia. Ictal surface EEG showed a discharge of rhythmic spikes beginning simultaneously with the cough, at right anterior temporal electrodes, then spreading to the right posterior electrodes. With the context of presurgical evaluation, SEEG was subsequently performed with 10 intracerebral electrodes to explore the right temporal, insulo-opercular, frontal inferior, and parietal inferior regions (*figure 1*). Signals were recorded on a 128-channel Natus™ system. These were sampled at 512 Hz. Interictal analysis revealed a slow delta/lesional activity on the right amygdala and hippocampus, and high-voltage spikes recorded over the right amygdala, hippocampus, and rhinal cortex.

Connectivity analysis

Connectivity analysis was conducted to determine brain network changes during coughing, as previously reported for other clinical changes during seizures or electrical stimulation (Bartolomei *et al.*, 2017a, 2017b). Interdependencies between SEEG signals were estimated with Anywave software (Colombet *et al.*, 2015) which computes a pairwise non-linear regression analysis based on the h^2 coefficient. In summary, a piecewise linear regression is performed between each pair of signals, testing all the shifts of one signal relative to the other within a maximum lag.

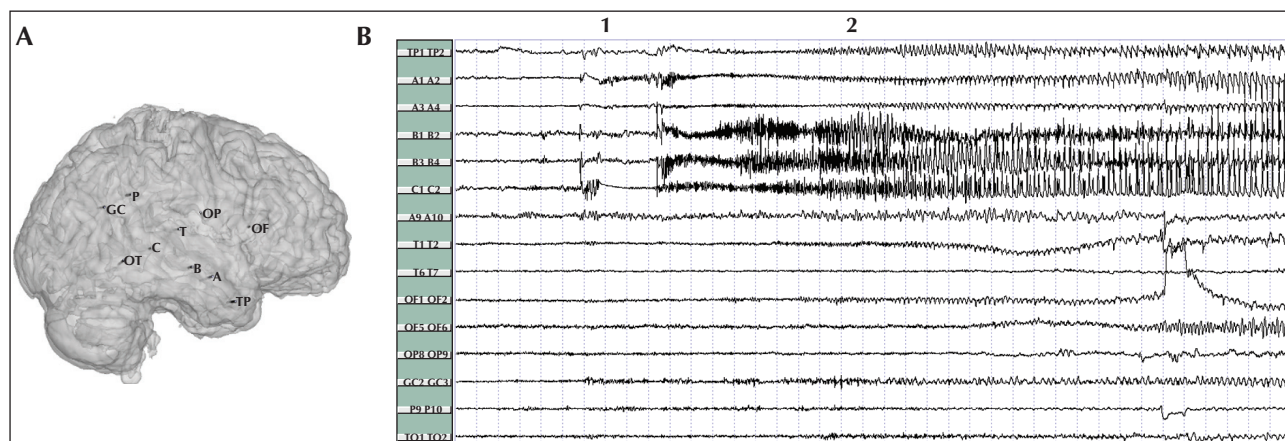


Figure 1. (A) SEEG implantation showing the electrodes on a 3D MRI mesh of the cortex (right side). Intracerebral electrodes are implanted under stereotactic conditions in Talairach's reference frame. Electrodes are identified by letter (A, etc.) and the electrode contacts are numbered from 1 to 15; low numbers corresponding to the deepest structures (for example, leads A1-2 recorded the electrical activity of the amygdala). A: Amygdala (medial contacts), and anterior part of middle temporal gyrus (MTG, lateral contacts); B, C: anterior, posterior hippocampus (medial contacts), medial, posterior part of MTG (lateral contacts); T: insula (medial contacts) and anterior part of superior temporal gyrus (STG, lateral contacts); TP: temporal pole; OF: caudate nucleus (internal contacts 1-2; operculo insular cortex); GC: cingulum (medial contacts), inferior parietal gyrus (lateral contacts); P: superior parietal cortex. (B) SEEG recorded seizure with selection of some bipolar traces. Bipolar signals were obtained by subtracting the signals recorded from two adjacent leads: 1: seizure onset marked by a rapid discharge affecting the mesial temporal region; 2: coughing onset. Note the appearance of a discharge in some other contacts (OF1-2: caudate nucleus; T1-2: insular region).

The h^2 is the coefficient of determination that measures the goodness of fit of the non-linear regression. The h^2 is bounded between 0 (no correlation) and 1 (maximal correlation) (Wendling and Bartolomei, 2001). We used a sliding window of 4 seconds with an overlap of 2 seconds and a maximum delay between signals of 100 ms. Signals were filtered using the Anywave software (Colombet *et al.*, 2015) (available at <http://meg.univ-amu.fr/wiki/AnyWave>), with Butterworth filters of order 4. We used only a 0.5-Hz high-pass filter for all analyses.

Graph measures

For all selected channels (each channel being a bipolar derivation), we computed all the pairwise h^2 values. Between two channels, we selected the higher h^2 value between $\text{chan1} \rightarrow \text{chan2}$ and $\text{chan2} \rightarrow \text{chan1}$. We thus obtained connectivity graphs, with each channel representing a node of the graph, and h^2 values the strength of the link between two nodes. We summarized the connectivity graphs with one related graph measure, node degrees, that first involves thresholding the graphs, and then counting the number of significant links between a given node and the rest of the graph. The threshold was set empirically to 0.25.

Statistical analysis

Node degrees were compared between a period preceding the seizure onset (background [BKG]) and the seizure periods, in particular, the seizure onset and the period in which the coughing occurred. Comparisons were performed using a Wilcoxon non-parametric paired test and Bonferroni correction was applied.

Results

During SEEG video monitoring (after partial reduction of antiepileptic drugs), two habitual seizures were recorded; one during sleep and one during wakefulness. On SEEG, seizures started with a low-voltage fast discharge beginning simultaneously within the amygdala, hippocampus, and rhinal cortex, and then spreading to the temporal polar region (*figure 1*). Only one seizure (during wakefulness) was characterized by prominent coughing. Coughing was the first visible clinical manifestation, without hypersalivation or sniffing. This began 18 seconds after the electrical SEEG seizure onset. At the time of coughing appearance, a rhythmic discharge was apparent in the caudate nucleus (OF1-3), the antero-inferior insular cortex (T1-2 electrode), and the lateral temporal cortex.

Coughing onset was followed by a facial expression of disgust, and other clinical signs (oral automatisms, gustatory hallucination [bad taste], and right dystonic posturing). At this time, a discharge extending to the insulo-opercular region was clearly observed (*figure 1B*).

A connectivity study (*figure 2*) was performed between 14 bipolar derivations recording different brain areas. This analysis revealed that seizure onset was associated with connectivity changes mostly limited to the right temporal mesial regions (increased connectivity). During the coughing phase, significant change characterized by increased connectivity was observed affecting a large part of the studied regions both in terms of strength of connectivity and degree (*figure 2A*). During coughing, a network extending over the mesial temporal regions and affecting the caudate nucleus (OF1-2) and the perisylvian cortex was observed. Node degrees increased significantly at seizure onset in the hippocampus and the amygdala. During coughing, and compared to seizure onset, node degree increase was observed in the amygdala, hippocampus, temporal neocortex, insular cortex, parietal cortex, opercular parietal cortex, and caudate nucleus.

Discussion

Ictal coughing remains a rare finding among epileptic patients, and its actual incidence remains unknown. Most previous studies did not differentiate ictal from post-ictal coughing, even though their physiopathology is probably distinct, leading to a global incidence of peri-ictal coughing in 9-40% of patients with temporal lobe epilepsy (Fauser *et al.*, 2004, Musilova *et al.*, 2010). Post-ictal coughing is probably a reaction to increase in oronasal secretions during the seizure due to excessive autonomic (parasympathetic) activation. Pure ictal coughing seems to be rarer, with only one published study reporting a prevalence of 0.16% and no localizing value (Asadi-Pooya *et al.*, 2017). One study (using both surface and intracranial EEG recording) described “peri-ictal” coughing (without distinguishing between ictal and post-ictal states) and reported that coughing, as a regular element of seizure semiology, was found only in temporal lobe seizures (Fauser *et al.*, 2004). Coughing shares some similarities with sneezing, notably concerning its reflex component mediated by the brainstem respiratory centres. Sneezing has been reported as a vegetative symptom of temporal lobe seizures during video-EEG recordings. The authors of this report suggest the involvement of mesial temporal structures, including the amygdala (Rodriguez-Osorio *et al.*, 2013). Another report suggested that ictal cough is more often seen in

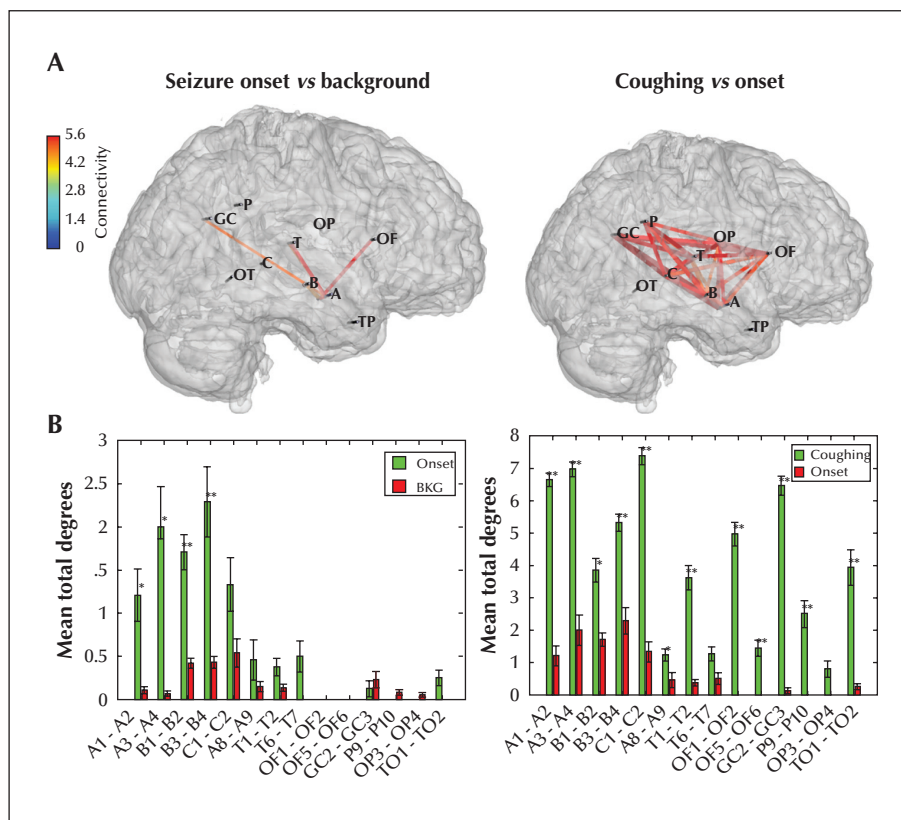


Figure 2. Connectivity analysis. (A) Changes in connectivity during seizure onset and during coughing; mean values over periods of 10 seconds are compared. Significant changes of connectivity are illustrated on a 3D mesh of the MRI with the position of electrodes. Only the significant changes are indicated for the seizure onset relative to the background period and for the coughing period relative to the onset. Colour scale indicates the p values of the Z-scores. (B) For each bipolar channel, the degrees are indicated between the different conditions (onset versus background and coughing versus onset) *indicates significant interactions ($*p < 0.05$, $**p < 0.01$ following Bonferroni correction).

non-dominant temporal epilepsy (Foldvary-Schaefer and Unnwongse, 2011), as was the case for our patient, but across studies, lateralization of this sign is unclear (Janszky *et al.*, 2007).

Cough is a motor act initiated by a medullary central cough centre, but which can be modulated by cortical influences. Indeed, fMRI experiments have shown the activation of regions involved in sensory perception (somatosensory cortex and lower parietal cortex) or voluntary cough control/suppression (central grey nuclei, motor cortex, SMA, and cingulate gyrus) (Mazzone *et al.*, 2013). Another fMRI study of the “urge to cough” phenomenon identified widespread brain activations involving the insula, anterior cingulate, primary sensory cortex, supplementary motor area, orbitofrontal cortex, and cerebellum (Mazzone *et al.*, 2007). The authors commented that a common cortical network might be implicated in sensing and shaping behavioural responses to a range of somatic and visceral stimuli.

In our patient, the onset of cough was associated with a discharge extending to subcortical (caudate)

and insula regions before rapidly spreading to other cortical regions. The analysis of connectivity changes showed a strong increase in connections within the perisylvian cortex, the caudate region, the parietal cortex, and the cingulate gyrus in particular. It is plausible, if not likely, that other regions not sampled by the SEEG are involved in these changes in network activity. It seems reasonable to assume that connectivity changes in the cortico-subcortical networks involved in voluntary execution and cough control are related to the production of coughing in this patient. The involvement of this distributed network may also account for ictal coughing occasionally observed in seizures of other cortical origin (Asadi-Pooya *et al.*, 2017). □

Supplementary data.

Summary didactic slides are available on the www.epilepticdisorders.com website.

Disclosures.

None of the authors have any conflict of interest to declare.

References

- Asadi-Pooya AA, Shabo L, Wyeth D, Nei M. Ictal coughing: clinical features and differential diagnoses. *Epilepsy Behav* 2017; 73: 51-3.
- Bartolomei F, Guye M, Wendling F. Abnormal binding and disruption in large scale networks involved in human partial seizures. *EPJ Nonlinear Biomed Phys* 2013; 1.
- Bartolomei F, Lagarde S, Lambert I, et al. Brain connectivity changes during ictal aggression (a strangulation attempt). *Epileptic Disord* 2017a; 19: 367-73.
- Bartolomei F, Lagarde S, Medina Villalon S, Mcgonigal A, Benar CG. The "Proust phenomenon": odor-evoked autobiographical memories triggered by direct amygdala stimulation in human. *Cortex* 2017b; 90: 173-5.
- Bartolomei F, Lagarde S, Wendling F, et al. Defining epileptogenic networks: contribution of SEEG and signal analysis. *Epilepsia* 2017c; 58: 1131-47.
- Chang AB. The physiology of cough. *Paediatr Respir Rev* 2006; 7: 2-8.
- Colombet B, Woodman M, Badier JM, Benar CG. AnyWave: a cross-platform and modular software for visualizing and processing electrophysiological signals. *J Neurosci Methods* 2015; 242: 118-26.
- Fauser S, Wuwer Y, Gierschner C, Schulze-Bonhage A. The localizing and lateralizing value of ictal/postictal coughing in patients with focal epilepsies. *Seizure* 2004; 13: 403-10.
- Foldvary-Schaefer N, Unnwongse K. Localizing and lateralizing features of auras and seizures. *Epilepsy Behav* 2011; 20: 160-6.
- Janszky J, Fogarasi A, Toth V, et al. Peri-ictal vegetative symptoms in temporal lobe epilepsy. *Epilepsy Behav* 2007; 11: 125-9.
- Mazzone SB, MCGovern AE, Yang SK, et al. Sensorimotor circuitry involved in the higher brain control of coughing. *Cough* 2013; 9: 7.
- Mazzone SB, McLennan L, MCGovern AE, Egan GF, Farrell MJ. Representation of capsaicin-evoked urge-to-cough in the human brain using functional magnetic resonance imaging. *Am J Respir Crit Care Med* 2007; 176: 327-32.
- Moinard J, Manier G. Physiology of cough. *Rev Mal Respir* 2000; 17: 23-8.
- Musilova K, Kuba R, Brazdil M, Tyrlikova I, Rektor I. Occurrence and lateralizing value of "rare" peri-ictal vegetative symptoms in temporal lobe epilepsy. *Epilepsy Behav* 2010; 19: 372-5.
- Rodriguez-Osorio X, Lopez-Gonzalez J, Lopez-Ferreiro A, Dominguez-Lorenzo JM, Peleteiro-Fernandez M. Postictal sneeze: an old but still under-recognized epileptic symptom. *Seizure* 2013; 22: 911-2.
- Wendling F, Bartolomei F. Modeling EEG signals and interpreting measures of relationship during temporal-lobe seizures: an approach to the study of epileptogenic networks. *Epileptic Disord* 2001; Special Issue: 67-78.

TEST YOURSELF



- (1) In which type of focal seizure can an early and severe cough be observed?
- (2) Which neural network is involved in ictal cough according to the results of the current study?

Note: Reading the manuscript provides an answer to all questions. Correct answers may be accessed on the website, www.epilepticdisorders.com, under the section "The EpiCentre".